

# The Augmentation of Revision Anterior Cruciate Ligament Reconstruction With Modified Iliotibial Band Tenodesis to Correct the Pivot Shift

## A Computer Navigation Study

Mark D. Porter,<sup>\*†</sup> FACSP, FRACS (Orth), DSc, Bruce Shadbolt,<sup>‡</sup> PhD, and Samantha Pomroy,<sup>†</sup> BPhys, MBBS  
*Investigation performed at Barton Private Hospital, Barton, Australia*

**Background:** Iliotibial band (ITB) tenodesis improves stability and functional outcomes when added to anterior cruciate ligament (ACL) reconstruction. Its precise indications are unknown. Persistence of the pivot shift after revision ACL reconstruction may be one indication.

**Hypothesis:** The addition of ITB tenodesis for a persistent pivot shift after revision ACL reconstruction will improve stability and activity levels.

**Study Design:** Cohort study; Level of evidence, 2.

**Methods:** Adults with recurrent ACL ruptures underwent revision ACL reconstruction, followed by a pivot-shift test before the surgery ended. If the pivot shift was grade 0 or 1, no further surgery was performed (group 1). If it was grade 2 or 3, ITB tenodesis was performed (group 2). The pivot-shift test was performed, graded, and measured using computer navigation before revision ACL reconstruction and after revision ACL reconstruction with and without ITB tenodesis. Tegner activity scores were obtained 2 years after surgery. Groups were compared with regard to anterior translation and internal rotation during the pivot shift as well as Tegner activity scores ( $P < .05$ ).

**Results:** There were 20 patients in group 1 and 18 in group 2. The mean anterior translation improved in group 1, from  $17.7 \pm 3.5$  mm to  $6.6 \pm 1.9$  mm, and group 2, from  $18.5 \pm 3.3$  mm to  $6.1 \pm 1.2$  mm, after revision ACL reconstruction ( $P < .001$ ), with no difference between the groups ( $P = .15$ ). After ITB tenodesis, the reduction in anterior translation in group 2 ( $5.3 \pm 1.5$  mm) became greater than that in group 1 ( $6.6 \pm 1.9$  mm) ( $P = .03$ ). In both groups after revision ACL reconstruction, there was a reduction in internal rotation (group 1:  $24.2^\circ \pm 4.0^\circ$  to  $10.3^\circ \pm 1.1^\circ$ ; group 2:  $25.4^\circ \pm 3.7^\circ$  to  $14.6^\circ \pm 2.8^\circ$ ;  $P < .001$ ), but this change was less in group 2 ( $P = .02$ ). After ITB tenodesis, internal rotation in group 2 ( $8.3^\circ \pm 2.6^\circ$ ) became less than that in group 1 ( $10.3^\circ \pm 1.1^\circ$ ) ( $P = .02$ ). The mean Tegner activity scores in group 1 were  $8.1 \pm 1.1$  before surgery and  $7.4 \pm 0.9$  after surgery, while in group 2 they were  $7.0 \pm 1.3$  and  $7.2 \pm 0.4$ , respectively, and not significantly different ( $P = .29$ ).

**Conclusion:** ITB tenodesis improved laxity, although it did not affect activity levels, when there was a persistent pivot shift after revision ACL reconstruction.

**Clinical Relevance:** An indication to perform ITB tenodesis is the persistence of a grade  $\geq 2$  pivot shift after revision ACL reconstruction.

**Keywords:** ACL reconstruction; revision; pivot shift; ITB tenodesis

Although anterior cruciate ligament (ACL) reconstruction is a successful operative procedure, up to one-quarter of patients may be unsatisfied with the outcome, as determined by International Knee Documentation Committee (IKDC) scores and return to sport.<sup>2,11,14,22</sup> Persistent laxity, rotational laxity in

particular, associated with a positive pivot shift has been associated with poor patient-reported outcomes after ACL reconstruction.<sup>21,22,25</sup> The pivot-shift test is the most clinically useful assessment for anterolateral rotatory instability, and it is possible to accurately measure the translation and rotation that occur during this test using computer navigation.<sup>23,28,29,35</sup>

Several approaches have been attempted to improve the rotational control achieved with ACL reconstruction. One technique is double-bundle reconstruction, which, although

TABLE 1  
Inclusion and Exclusion Criteria<sup>a</sup>

Inclusion Criteria	Exclusion Criteria
Recurrent unilateral ACL rupture	Revision surgery not indicated
One previous ACL reconstruction, with an available hamstring autograft for the revision procedure	Not fit for general anesthetic
Suitable for single-stage revision	Two-stage revision ACL reconstruction indicated
Skeletally mature	No history of rheumatological disease or connective tissue disease
Able to provide written informed consent	

<sup>a</sup>ACL, anterior cruciate ligament.

shown to improve rotational control,<sup>42,51</sup> provides no clinical superiority.<sup>52</sup> Other research has shown that by using a single-bundle reconstruction technique with optimal tunnel placement and aperture fixation, it is possible to control both the anterior translation (AT) and internal rotation (IR) that occur during the pivot shift after an isolated ACL rupture.<sup>36,37</sup>

It has been suggested that the persistent rotational instability seen after ACL reconstruction in some patients is caused by peripheral injuries,<sup>1,30,34,39</sup> that is, injuries to anterolateral extra-articular tissue. In these cases, even optimal ACL reconstruction procedures may fail to control rotational laxity.<sup>45</sup> An alternative approach is to augment ACL reconstruction with an extra-articular anterolateral soft tissue procedure designed to resist IR of the tibia and compensate for the extra-articular component of the injury.<sup>17</sup>

For at least 75% of patients undergoing ACL reconstruction these additional extracapsular procedures are not required, and their precise indications remain a topic of debate. Concerns remain that, although an extra-articular procedure may reduce loads on an ACL graft and thus may protect it from a reinjury, the extra-articular procedure may also result in overconstraint of the knee with potential adverse effects.<sup>8,16,40</sup>

These extracapsular procedures may be indicated in the setting of revision ACL reconstruction,<sup>9,10</sup> patients with a gross pivot shift,<sup>4,7,30,44</sup> and those with a residual pivot shift after ACL reconstruction.<sup>34,46</sup> One such extra-articular procedure is iliotibial band (ITB) tenodesis, and Monaco et al<sup>31,32</sup> have shown that a modification of this procedure acts synergistically with the ACL graft, controlling the rotation that occurs during the pivot shift at the time of surgery.

The goal of our study was to determine in vivo if the addition of an ITB tenodesis procedure in those patients with a persistent pivot shift after revision ACL reconstruction reduced AT and IR during the pivot shift. We also wanted to compare the activity levels in those patients who underwent revision ACL reconstruction with and without ITB tenodesis 2 years after surgery. Our hypothesis was that the addition of ITB tenodesis to revision ACL reconstruction

would reduce both AT and IR during the pivot shift and that the Tegner activity scores would be improved.

## METHODS

The study was approved by the institutional ethics committee at Barton Private Hospital, where the surgical procedures were performed. During the period from January 2012 to December 2014, all patients presenting to the main author (M.D.P.) with a recurrent ACL rupture and who satisfied the study criteria in Table 1 were invited to take part in the study. All operative procedures were performed by the main author.

### Navigation and Pivot-Shift Technique

Although variations in the technique have been used, we performed the pivot-shift test with valgus stress, IR, and moving the knee from full extension to flexion.<sup>12,18,25</sup> Computer navigation has enabled objective measurement of the pivot shift,<sup>34</sup> and it has been shown to have an intrasurgeon reliability of less than 1 mm for AT and less than 1.6° for IR.<sup>28</sup> We used an infrared computerized navigation system (OrthoPilot; B. Braun Melsungen AG) with intraosseous fixation of the optical arrays as described in the literature.<sup>36,37</sup> The amount of AT and IR during each performance of the pivot-shift test on the operative knee was recorded. The main author performed the pivot-shift test on all occasions but was blinded to the results of navigation at the time of surgery.

### Surgical Technique

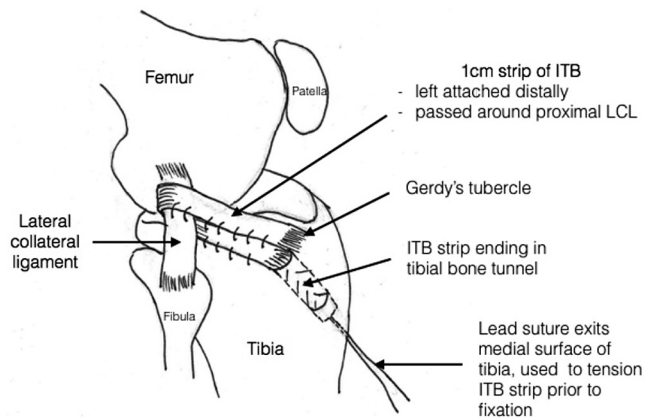
**ACL Reconstruction.** Tourniquets were placed on both limbs, inflated on the injured side, and standard arthroscopic surgery performed, during which it was determined whether single-stage revision was possible. Any meniscal lesions and/or chondral lesions were treated as appropriate, and the ACL graft remnants were debrided. After

\*Address correspondence to Mark D. Porter, FACSP, FRACS (Orth), DSc, Canberra Orthopaedics and Sports Medicine, Calvary Clinic, 21/40 Mary Potter Circuit, Suite 21, Bruce, ACT 2617, Australia (email: mdporter@iinet.net.au).

<sup>†</sup>Canberra Orthopaedics and Sports Medicine, Calvary Clinic, Bruce, Australia.

<sup>‡</sup>Department of Epidemiology, Canberra Hospital, Garran, Australia.

The authors declared that they have no conflicts of interest in the authorship and publication of this contribution.



**Figure 1.** Iliotibial band tenodesis technique (modified Lemaire procedure). ITB, iliotibial band; LCL, lateral collateral ligament.

this, the pivot-shift test was performed, graded, and recorded using computer navigation. The hamstring tendons were harvested from the contralateral thigh to make a quadrupled soft tissue graft. The ACL bone tunnels were positioned within the footprints, as described in the literature.<sup>36</sup> The graft was fixed on the femoral side using titanium interference screws (BioRCI; Smith & Nephew), hand tensioned in full extension, and then fixed on the tibial side using biocomposite interference screws (BioRCI HA; Smith & Nephew).

After revision ACL reconstruction, the pivot-shift test was repeated, graded, and navigated. If there was a grade 0 or 1 pivot shift, no further surgery was performed (group 1); if there was a grade  $\geq 2$  pivot shift, the ITB tenodesis procedure was performed (group 2).

**ITB Tenodesis.** The main author used a technique similar to the modified Lemaire procedure<sup>32</sup> but modified further with regard to the course of the graft around the lateral collateral ligament (LCL), going superficial to deep as proximally as possible, and at the tibial attachment, where it was secured in a bone tunnel longer in length than that of the intraosseous tendon (Figure 1). This method of fixation enabled both a bone graft to be harvested for 2-stage revision as well as tension to be adjusted so that it only corrected the pivot shift without overrestraining the knee.

A lateral incision, approximately 15 cm in length, was made running from the Gerdy tubercle proximally, posterior to the lateral femoral epicondyle, along the ITB. A central 1  $\times$  15-cm strip of the ITB was harvested, left attached distally, and the free end prepared with a traction suture whipstitch. The ITB graft was passed around the proximal LCL and then into the bone tunnel positioned posterior to the Gerdy tubercle. The bone tunnel was 6 mm in diameter and 3 cm long, and the traction suture exited the bone through a second 2-mm tunnel at the medial cortex. Tension on the lead suture allowed the adjustment of tension in the looped graft before its fixation. Hand tension was applied with the tibia in neutral rotation. Tension was adjusted until the ITB tenodesis procedure only corrected the pivot shift to grade 0 to 1 before

fixation using a 30  $\times$  7-mm interference screw (BioRCI HA) with the knee flexed to 35°. The rerouted strip of the ITB was stitched to itself, the LCL, and the anterolateral capsule of the knee joint. After this, the ITB interval was closed, and then the pivot-shift test was repeated, graded, and navigated. The amount of AT and IR occurring during each pivot-shift test before ACL reconstruction, immediately after revision ACL reconstruction, and immediately after ITB tenodesis, when performed, was recorded.

### Tegner Activity Scale and Follow-up

The Tegner activity scale is a numerical scale with values from 0 to 10 representing specific activities. Values of 10 represent the highest activity level (such as one of the codes of football at the elite level) and 0 the lowest. It is a validated patient assessment score for ACL injuries with a minimal detectable value of 1.<sup>5</sup> Patients were asked to complete it before surgery based on the level of activity immediately before their recurrent ACL ruptures. They were also asked to complete it 2 years after the revision procedure. Patients were prospectively followed up, and the occurrence of any complications, further surgery, and/or recurrence of ACL ruptures were noted.

### Statistical Analysis

Statistical analysis was performed using SPSS (v22; IBM Corp). Using analysis of variance, group 1 and group 2 were compared with regard to their preoperative Tegner activity scores and the AT and IR recorded during the first pivot-shift test performed with the patient under general anesthesia immediately before surgery. *t* tests were used to compare the delay before revision surgery and age at the time of revision surgery in the 2 groups.

Using generalized linear models and multivariate tests, we compared the 2 groups with regard to the reduction in AT and IR after revision ACL reconstruction, the reduction in AT and IR upon the completion of surgery, and Tegner activity scores 2 years after surgery. We performed both parametric and nonparametric analyses.

### Power Analysis

If 2 mm of AT and 2° of IR are regarded as clinically important, as have been used previously in the literature,<sup>36,37</sup> to detect a difference in the mean values between the groups significant with 95% confidence and a power of 80%, 16 patients were required in each group. If 1 point is regarded as clinically important, to detect a difference in the mean Tegner activity scores in the 2 groups significant with 95% confidence and a power of 80%, again 16 patients were required in each group.

## RESULTS

During the study period, a total of 61 patients were seen with recurrent ACL ruptures. Twenty-three of these were not candidates for a single-stage revision procedure on

the basis of bone deficits and/or the previous tunnel position ( $n = 11$ ), the severity of osteoarthritis present in the knee ( $n = 4$ ), unwillingness to undergo a revision procedure ( $n = 2$ ), or the presence of marked polyethylene synovitis after using the LARS ligament (Surgical Implants and Devices) that required total synovectomy and 2-stage revision ( $n = 6$ ). This left 38 patients, all of whom consented to take part in the study.

In the 38 study patients, the mean age was  $25.2 \pm 6.0$  years, with a male:female ratio of 18:20. Of the 38 patients, 20 (53%) had a grade 0 or 1 pivot shift after revision ACL reconstruction and formed group 1, while the remaining 18 patients (47%) had a grade 2 or 3 pivot shift after revision ACL reconstruction, underwent ITB tenodesis, and formed group 2.

The mean age in group 1 ( $22.6 \pm 2.4$  years) was lower than that in group 2 ( $28.2 \pm 7.2$  years) ( $P = .008$ ), and the mean delay between reinjury and revision surgery was shorter in group 1 ( $5.8 \pm 4.4$  months) than in group 2 ( $15.2 \pm 11.3$  months) ( $P = .002$ ). The male:female ratio was 9:11 in group 1 and 9:9 in group 2. Overall, the injured knee was described as dominant in 14 and nondominant in 24. In group 1, the dominant:nondominant ratio was 7:13 and in group 2 was 7:11. None of the 38 patients had an osteochondral lesion. Four patients in group 1 and 3 in group 2 required partial meniscectomy. One patient in each group had lateral meniscal repair performed.

### Baseline Data

Before revision surgery, the mean AT was  $18.1 \pm 3.4$  mm, and the mean IR was  $24.7^\circ \pm 3.9^\circ$ , and the mean Tegner activity score before the recurrence of ACL ruptures was  $7.6 \pm 1.3$  in the 38 patients. The AT ( $17.7 \pm 3.5$  mm vs  $18.5 \pm 3.3$  mm, respectively) and IR ( $24.2^\circ \pm 4.0^\circ$  vs  $25.4^\circ \pm 3.7^\circ$ , respectively) were similar in group 1 and group 2 ( $P = .48$  and  $P = .33$ , respectively). The mean Tegner activity score was significantly higher in group 1 ( $8.1 \pm 1.1$ ) relative to group 2 ( $7.0 \pm 1.3$ ) ( $P = .01$ ).

In group 1, 10 patients (50%) had a grade 2 pivot shift, and 10 (50%) had a grade 3 pivot shift before surgery, while in group 2, the values were 8 (44%) and 10 (56%), respectively. In group 1, the pivot-shift test finding of the contralateral uninjured knee was grade 0 in 17 patients (85%) and grade 1 in 3 patients (15%), while in group 2, the values were 15 (83%) and 3 (17%), respectively.

### Computer Navigation Results

**AT During the Pivot-Shift Test.** There was a significant reduction in AT in both group 1 ( $17.7 \pm 3.5$  mm to  $6.6 \pm 1.9$  mm) and group 2 ( $18.5 \pm 3.3$  mm to  $6.1 \pm 1.2$  mm) after ACL reconstruction ( $P < .001$ ), while the difference between the 2 groups was not significant ( $P = .15$ ). When the ITB tenodesis procedure was added, the improvement in AT became statistically significant in group 2 ( $5.3 \pm 1.5$  mm) relative to group 1 ( $6.6 \pm 1.9$  mm) ( $P = .03$ ).

**IR During the Pivot-Shift Test.** There was a significant reduction in IR in both group 1 ( $24.2^\circ \pm 4.0^\circ$  to  $10.3^\circ \pm 1.1^\circ$ ) and group 2 ( $25.4^\circ \pm 3.7^\circ$  to  $14.6^\circ \pm 2.8^\circ$ ) after ACL

reconstruction ( $P < .001$ ), with a greater reduction in group 1 relative to group 2 ( $P = .02$ ). When the ITB tenodesis procedure was added, there was a greater reduction in IR in group 2 ( $8.3^\circ \pm 2.6^\circ$ ) relative to group 1 ( $10.3^\circ \pm 1.1^\circ$ ) ( $P = .02$ ).

**Tegner Activity Scores.** In group 1, the mean Tegner activity scores were  $8.1 \pm 1.1$  before surgery and  $7.4 \pm 0.9$  at 2 years after surgery. In group 2, these values were  $7.0 \pm 1.3$  and  $7.2 \pm 0.4$ , respectively. The final scores were similar in the 2 groups ( $P = .29$ ).

### Complications and Further Procedures

There were no further ACL ruptures on the injured side in either group. However, in group 1, there were 2 patients in whom there was a rupture of the contralateral ACL. One patient in group 2 had a superficial wound infection at the ITB tenodesis site, which settled with a course of oral antibiotics.

Two patients in each group required a second operative procedure on the knee that had undergone revision ACL reconstruction. In group 1, one patient had a lateral meniscal tear 13 months after surgery that was treated with meniscal repair, and one had ongoing anterolateral instability with an intact revision ACL reconstruction construct and had ITB tenodesis performed 18 months after surgery. In group 2, there was 1 medial meniscal tear treated with partial meniscectomy and 1 case of arthrofibrosis treated with arthroscopic debridement and manipulation under anesthesia. There were no further ACL injuries in either group.

### DISCUSSION

Our study has found that 47% of the patients undergoing revision ACL reconstruction had a residual grade  $\geq 2$  pivot shift immediately after surgery. These patients had a lower Tegner activity score before recurrence, a higher age at the time of revision surgery, and a longer delay between reinjury and revision surgery. The addition of ITB tenodesis to revision ACL reconstruction in these patients restored their pivot shift to normal and reduced both the amount of AT and IR that occur during the pivot-shift test. The final mean AT in group 2 was  $5.3 \pm 1.5$  mm, which was less than that in group 1 ( $6.6 \pm 1.9$  mm) ( $P = .03$ ), but this difference of only 1.3 mm is unlikely to be clinically relevant. Similar comments apply to the smaller final IR values in group 2 ( $8.3^\circ \pm 2.6^\circ$ ) compared with group 1 ( $10.3^\circ \pm 1.1^\circ$ ) ( $P = .02$ ). The addition of ITB tenodesis resulted in Tegner activity scores similar to those found in patients not undergoing ITB tenodesis. There were no further ACL injuries in either group over the 2-year follow-up period.

The pivot-shift test is the most clinically useful assessment available for examining anterolateral rotatory instability of the knee.<sup>29</sup> Persistent rotational instability and a positive pivot shift after ACL reconstruction may be caused by intra-articular and/or extra-articular factors. Several approaches have been used to improve the rotational control achieved with ACL reconstruction. One approach has been to concentrate on the intra-articular



factors and maximize the function of single-bundle ACL reconstruction. Improved understanding of the footprint anatomy, graft placement, and fixation has resulted in a technique that can restore rotational control and translational control during the pivot-shift test using a single-bundle technique and aperture fixation in acute, isolated ACL ruptures.<sup>36,37</sup> However, this may only apply to isolated ACL injuries. Research has shown that the persistence of rotational instability after ACL reconstruction may be because of unrecognized peripheral injuries causing persistent rotational instability,<sup>1,30,34,39</sup> and this may explain why, in some patients, ACL reconstruction is not sufficient to restore normal rotational stability to the knee.<sup>45</sup>

Another technique focusing on the intra-articular factors is the use of double-bundle ACL procedures. This technique is based on the assumption that the addition of a second intra-articular bundle to the ACL may improve rotational control and outcomes. The double-bundle technique may improve rotational control when compared with anatomic anteromedial single-bundle reconstruction,<sup>42,51</sup> but it has been found to offer no clinical superiority.<sup>52</sup>

Another approach has been to address the extra-articular component of the injury believed to contribute to the persistent rotational instability that may be present after ACL reconstruction. The relative importance of the soft tissue structures at the anterolateral aspect of the knee in relation to rotational laxity has been debated.<sup>48</sup> Renewed interest in the anterolateral ligament (ALL) of the knee was ignited by Claes et al,<sup>6</sup> whose studies have detailed the anatomy of this ligament, and others have demonstrated its role in controlling IR of the tibia.<sup>34</sup>

Other research has suggested that the iliotibial tract (ITT) may be more important. Kittl et al<sup>20</sup> performed a sequential resection study using cadaveric knees and a robotic testing protocol. They found that the deep and superficial fibers of the ITT were the primary restraints to tibial IR during a simulated pivot shift at 30° to 45°. They also found that the ITT was the primary restraint to tibial IR for both the intact and ACL-deficient knees from 30° to 90° of flexion, while the ALL had no significant restraining role. In their cadaveric study, short knee specimens were used with no proximal continuity to the musculotendinous structures, and this may have influenced the findings. The tibia and femur, including all soft tissues, were cut 120 mm and 200 mm from the joint line, respectively. The sectioning performed may not have replicated the complex structural damage that occurs in the patient with a combined ACL and anterolateral soft tissue injury. Terry et al<sup>47</sup> found that the deep and capsulo-osseous layer of the ITT is damaged in 93% of functionally unstable knees, and this damage correlated with the grade of pivot shift, while ACL damage did not.

It is possible that a number of soft tissue structures may play a role in rotational control, which may vary with patient anatomy and the specific nature of the injury to the knee. The anterolateral capsule of the knee joint has been shown to function as a sheet of tissue, transmitting forces between adjacent regions of the capsule at right angles to its longitudinal axis, rather than as a more

traditional ligament.<sup>13</sup> The study by Guenther et al<sup>13</sup> found that the interaction of the anterolateral capsule and LCL with adjacent soft tissues played a significant role in resisting internal torque of the tibia. The modified Lemaire procedure, which we used in our study, may act by increasing tension in the distal ITB and/or augmenting an anterolateral sheet of soft tissues.

It is now possible to objectively measure the AT and IR that occur during the pivot shift test using computer navigation at the time of surgery. The clinical success of an anterolateral soft tissue procedure used to augment ACL reconstruction may be measured by its ability to correct the residual pivot shift and to restore function to normal, as in this study. It was with this goal in mind that the authors modified the Lemaire technique so that tension of the construct could be adjusted to correct the pivot shift without overconstraining the knee. Research has shown that the pivot-shift phenomenon commences at 35°, moving from flexion to extension, and this is the angle at which the senior author adjusts and fixes the ITB tenodesis construct.<sup>36</sup> It may function both as a ligament, resisting forces parallel to its long axis, and as a sheet of fibrous tissue by binding together the LCL, anterolateral capsule, ALL, and ITB (Figure 1).

Although concerns have been raised that these anterolateral soft tissue procedures may increase the risk of lateral compartment osteoarthritis,<sup>41</sup> research has shown that these procedures do not overconstrain the knee, nor do they increase lateral tibiofemoral contact pressure or cause a loss of IR, as long as the graft is tensioned in neutral and not excessively.<sup>27</sup> Marcacci et al<sup>27</sup> found that the augmentation of ACL reconstruction with extra-articular tenodesis was not associated with an increased risk of osteoarthritis.

In patients with an ACL rupture combined with anterolateral soft tissue damage, it is possible that the peripheral injuries may heal in some patients. It is possible that a delay between the recurrence of the ACL rupture and revision surgery may contribute to delayed healing, healing in a lengthened position, and/or chronic attrition of these structures and thus persistence of the pivot shift after revision ACL reconstruction, as seen in our study. The fact that the patients in our study requiring ITB tenodesis were older than those not requiring it may be related to the increased delay referred to above and/or the performance of the original ACL procedure at a time when positioning of the ACL graft was less precise.

The challenge is how to select those patients who will benefit from the addition of an anterolateral procedure to ACL reconstruction using practical means. A residual pivot shift has been described as a significant negative predictive factor in patients undergoing ACL reconstruction,<sup>3,19,22,49</sup> and one subgroup of such patients may be those with a persistent pivot shift after ACL reconstruction in the revision setting.<sup>7</sup> It is for this reason that we used the presence of a grade  $\geq 2$  pivot shift after revision ACL reconstruction as the indication to perform the ITB tenodesis procedure. We did not regard a grade 1 pivot shift as sufficient to add ITB tenodesis, and this grade of pivot shift was found in 16% of the normal contralateral knees. Other authors have suggested that an obvious grade 2 or

3 pivot shift is an indication to perform anterolateral tenodesis,<sup>4,10,44,50</sup> but this idea is contentious. Rotational laxity may induce higher ACL graft forces,<sup>24</sup> with a potential increased risk of recurrence of ACL ruptures, and may cause the early onset of osteoarthritis.<sup>45</sup>

However, there may be other indications, such as those patients with high-grade knee laxity and an increased risk of recurrence after ACL reconstruction.<sup>26</sup> Our study found that correction of the pivot shift did not affect Tegner activity scores 2 years after surgery. Further research may assist in developing more precise indications for extracapsular augmentation procedures such as ITB tenodesis.

These patients will be followed up longer term to determine if their Tegner activity scores change and to document any complications such as osteoarthritis. A number of meta-analyses have found that the addition of anterolateral tenodesis to ACL reconstruction is not associated with an increased risk of complications,<sup>15,38,43</sup> and Noyes and Barber<sup>33</sup> found a significant reduction in the rate of recurrent ACL ruptures when an extracapsular procedure was added.

A weakness in our study design was that patients were not randomly allocated to 2 treatment groups, and the groups differed with regard to the presence of a grade 2 pivot shift after revision ACL reconstruction. A randomized controlled trial in which only 50% of those patients with a persistent pivot shift have ITB tenodesis added may have resulted in a more even distribution of confounders, but we found that the patients who satisfied the inclusion criteria were unwilling to take part in a randomized controlled trial with a 50% chance of not undergoing ITB tenodesis once the rationale was explained to them. However, the goal of our study was to determine if the addition of ITB tenodesis resulted in the restoration of normal laxity in this subgroup of patients, and each patient who had ITB tenodesis performed acted as his or her own control, and the patients who had only revision ACL reconstruction performed acted as a surrogate control group.

Our study groups also differed with regard to age, delay before revision surgery, and Tegner activity score. The preoperative Tegner activity scores were higher in the group that did not require ITB tenodesis, and this would favor group 1, rather than group 2, with regard to final scores, which were similar in the 2 groups. The surgeon could not be blinded as to whether ITB tenodesis was performed but was blinded to the results of pivot-shift navigation during surgery. It was also impractical for the surgeon to use robotic devices to perform the pivot-shift test, and therefore, it is unlikely that a uniform force was used during the performance of the tests. One of the goals of surgery was to see if the performance of ITB tenodesis based on the outcome of a practical intraoperative assessment resulted in improvement in the pivot-shift grade, AT and IR, and/or Tegner activity score. Therefore, the study used the pivot-shift test performed in a manner similar to that done by the surgeon during ACL surgery. The study results refer to the computer-navigated pivot-shift test performed at the time of surgery, and how this correlates with the pivot-shift test performed at various intervals after surgery remains unknown. Although the size of the study is limited to 38 patients, a power analysis demonstrated

that it was sufficiently powered to detect significant changes in AT and IR during the pivot shift. Although there were no reported failures of revision surgery during the 2-year period of follow-up, the authors realize that this is a relatively brief period of time and too short to comment on any association with osteoarthritis. However, these patients are part of ongoing prospective work.

## CONCLUSION

We conclude that if ITB tenodesis is added to single-stage revision ACL reconstruction in the presence of a persistent grade  $\geq 2$  pivot shift, AT and IR during the pivot shift can be significantly improved, and there is no difference in activity levels seen in the 2 groups 2 years after surgery.

## REFERENCES

1. Amis AA, Bull AM, Lie DT. Biomechanics of rotational instability and anatomic anterior cruciate ligament reconstruction. *Oper Tech Orthop*. 2005;15(1):29-35.
2. Ardern CL, Webster KE, Taylor NF, Feller JA. Return to sport following anterior cruciate ligament reconstruction surgery: a systematic review and meta-analysis of the state of play. *Br J Sports Med*. 2011;45(7):596-606.
3. Ayeni OR, Chahal M, Tran MN, Sprague S. Pivot shift as an outcome measure for ACL reconstruction: a systematic review. *Knee Surg Sports Traumatol Arthrosc*. 2012;20(4):767-777.
4. Branch T, Lavoie F, Guier C, et al. Single-bundle ACL reconstruction with and without extra-articular reconstruction: evaluation with robotic lower leg rotation testing and patient satisfaction scores. *Knee Surg Sports Traumatol Arthrosc*. 2015;23(10):2882-2891.
5. Briggs KK, Lysholm J, Tegner Y, Rodkey WG, Kocher MS, Steadman JR. The reliability, validity, and responsiveness of Lysholm score and Tegner activity score for anterior cruciate ligament injuries of the knee: 25 years later. *Am J Sports Med*. 2009;37(5):890-897.
6. Claes S, Vereecke E, Maes M, Victor J, Verdonk P, Bellemans J. Anatomy of the anterolateral ligament of the knee. *J Anat*. 2013;223:321-328.
7. Duthon VB, Magnussen RA, Servien E, Neyret P. ACL reconstruction and extra-articular tenodesis. *Clin Sports Med*. 2013;32:141-153.
8. Engebretsen L, Lew WD, Lewis J, Hunter RE. The effect of an iliotibial tenodesis on intraarticular graft forces and knee joint motion. *Am J Sports Med*. 1990;18(2):169-176.
9. Ferretti A, Conteduca F, Monaco E, et al. Revision anterior cruciate ligament reconstruction with doubled semitendinosus and gracilis tendons and lateral extra-articular reconstruction. *J Bone Joint Surg Am*. 2006;88(11):2373-2379.
10. Ferretti A, Monaco E, Labianca L, De Carli A, Conteduca F. Double bundle or single bundle plus extra-articular tenodesis in ACL reconstruction? A CAOS study. *Knee Surg Sports Traumatol Arthrosc*. 2008;16(1):98.
11. Freedman KB, D'Amato MJ, Nedeff DD, Kaz A, Bach BR Jr. Arthroscopic anterior cruciate ligament reconstruction: a metaanalysis comparing patellar tendon and hamstring tendon autografts. *Am J Sports Med*. 2003;31(1):2-11.
12. Galway HR, MacIntosh DL. The lateral pivot shift: a symptom and sign of anterior cruciate ligament insufficiency. *Clin Orthop Relat Res*. 1980;147:45-50.
13. Guenther D, Rahnama-Azar AA, Bell KM, et al. The anterolateral capsule of the knee behaves like a sheet of fibrous tissue. *Am J Sports Med*. 2017;45(4):849-855.
14. Harner CD, Giffin JR, Duntzman RC, Annunziata CC, Friedman MJ. Evaluation and treatment of recurrent instability after anterior cruciate ligament reconstruction. *Instr Course Lect*. 2001;50:463-474.

15. Hewison CE, Tran MN, Kaniki N, Remtulla A, Bryant D, Getgood AM. Lateral extra-articular tenodesis reduces rotational laxity when combined with anterior cruciate ligament reconstruction: a systematic review of the literature. *Arthroscopy*. 2015;31(10):2022-2034.
16. Imbert P, Belvedere C, Leardini A. Knee laxity modifications after ACL rupture and surgical intra- and extra-articular reconstructions: intra-operative measures in reconstructed knees and healthy knees [published online June 3, 2015]. *Knee Surg Sports Traumatol Arthrosc*. doi:10.1007/s00167-015-3653-1.
17. Inderhaug E, Stephen J, Williams A, Amis A. Mechanical comparison of anterolateral procedures combined with anterior cruciate ligament reconstruction. *Am J Sports Med*. 2017;45(2):347-354.
18. Jakob RP, Staubli HU, Deland JT. Grading the pivot shift: objective tests with implications for treatment. *J Bone Joint Surg Br*. 1987;69(2):294-299.
19. Kaplan N, Wickiewicz TL, Warren RF. Primary surgical treatment of anterior cruciate ligament ruptures: a long-term follow-up study. *Am J Sports Med*. 1990;18:354-358.
20. Kittl C, El-Dao H, Athwal KK, et al. The role of the anterolateral structures and the ACL in controlling laxity of the intact and ACL-deficient knee. *Am J Sports Med*. 2016;44(2):345-354.
21. Kocher MS, Steadman JR, Briggs K, et al. Determinants of patient satisfaction with outcome after anterior cruciate ligament reconstruction. *J Bone Joint Surg Am*. 2002;84(9):1560-1572.
22. Kocher MS, Steadman JR, Briggs KK, Sterett WI, Hawkins RJ. Relationships between objective assessment of ligament stability and subjective assessment of symptoms and function after anterior cruciate ligament reconstruction. *Am J Sports Med*. 2004;32(3):629-634.
23. Kubo S, Muratsu H, Yoshiya S, Mizuno K, Kurosaka M. Reliability and usefulness of a new in vivo measurement system of the pivot shift. *Clin Orthop Relat Res*. 2007;454:54-58.
24. LaPrade RF, Resig S, Wentorf F, Lewis JL. The effects of grade III posterolateral knee complex injuries on anterior cruciate ligament graft force: a biomechanical analysis. *Am J Sports Med*. 1999;27(4):469-475.
25. Losee R, Johnson T, Southwick W. Anterior subluxation of the lateral tibial plateau: a diagnostic test and operative repair. *J Bone Joint Surg Am*. 1978;60:1015-1030.
26. Magnussen RA, Reinke EK, Huston LJ, MOON Group, Hewett TE, Spindler KP. Effect of high-grade preoperative knee laxity on anterior cruciate ligament reconstruction outcomes. *Am J Sports Med*. 2016;44(12):3077-3082.
27. Marcacci M, Zaffagnini S, Giordano G, et al. Anterior cruciate ligament reconstruction associated with extra-articular tenodesis: a prospective clinical and radiographic evaluation with 10- to 13-year follow-up. *Am J Sports Med*. 2009;37(4):707-714.
28. Martelli S, Zaffagnini S, Bignozzi S, Lopomo N, Marcacci M. Description and validation of a navigation system for intra-operative evaluation of knee laxity. *Comput Aided Surg*. 2007;12(3):181-188.
29. Matsumoto H. Mechanism of the pivot shift. *J Bone Joint Surg Br*. 1990;72:816-821.
30. Monaco E, Ferretti A, Labianca L, et al. Navigated knee kinematics after cutting of the ACL and its secondary restraint. *Knee Surg Sports Traumatol Arthrosc*. 2012;20(5):870-877.
31. Monaco E, Labianca L, Conteduca F, et al. Double bundle or single bundle plus extraarticular tenodesis in ACL reconstruction? A CAOS study. *Knee Surg Sports Traumatol Arthrosc*. 2007;15(10):1168-1174.
32. Monaco E, Maestri B, Conteduca F, Mazza D, Iorio C, Ferretti A. Extra-articular ACL reconstruction and pivot shift: in vivo dynamic evaluation with navigation. *Am J Sports Med*. 2014;42(7):1669-1674.
33. Noyes FR, Barber SD. The effect of an extra-articular procedure on allograft reconstructions for chronic ruptures of the anterior cruciate ligament. *J Bone Joint Surg Am*. 1991;73:882-892.
34. Parsons EM, Gee OA, Spiekerman C, Cavanagh PR. The biomechanical function of the anterolateral ligament of the knee. *Am J Sports Med*. 2015;43(3):669-674.
35. Pearle AD, Solomon DJ, Wanich T, et al. Reliability of navigated knee stability examination: a cadaveric evaluation. *Am J Sports Med*. 2007;35(8):1315-1320.
36. Porter M, Shadbolt B. "Anatomic" single-bundle anterior cruciate ligament reconstruction reduces both anterior translation and internal rotation during the pivot shift. *Am J Sports Med*. 2014;42(12):2948-2954.
37. Porter M, Shadbolt B. Femoral aperture fixation improves anterior cruciate ligament graft function when added to cortical suspensory fixation. *Orthop J Sports Med*. 2016;4(9):2325967116665795.
38. Rezende FC, de Moraes VY, Martimbianco ALC, Luzo MV, da Silveira Franciozi CE, Belloti JC. Does combined intra- and extraarticular ACL reconstruction improve function and stability? A meta-analysis. *Clin Orthop Relat Res*. 2015;473:2609-2618.
39. Ristanis S, Stergiou N, Patras K, Tsepis E, Moraiti C, Georgoulis AD. Follow-up evaluation 2 years after ACL reconstruction with bone-patellar tendon-bone graft shows that excessive tibial rotation persists. *Clin J Sport Med*. 2006;16(2):111-116.
40. Samuelson M, Draganich LF, Zhou X, Krumins P, Reider B. The effects of knee reconstruction on combined anterior cruciate ligament reconstruction on combined anterior cruciate ligament reconstruction and anterolateral capsular deficiencies. *Am J Sports Med*. 1996;24(4):492-497.
41. Schon JM, Moatshe G, Brady AW, et al. Anatomic anterolateral ligament reconstruction leads to overconstraint at any fixation angle. *Am J Sports Med*. 2016;44(10):2546-2556.
42. Schreiber VM, van Eck CF, Fu FH. Anatomic double-bundle ACL reconstruction. *Sports Med Arthrosc*. 2010;18:27-32.
43. Song G-Y, Hong L, Zhang H, Zhang J, Li Y, Feng H. Clinical outcomes of combined lateral extra-articular tenodesis and intra-articular anterior cruciate ligament reconstruction in addressing high-grade pivot-shift phenomenon. *Arthroscopy*. 2016;32(5):898-905.
44. Sonnery-Cottet B, Thauant M, Freychet B, Pupim BHB, Murphy CG, Claes S. Outcome of a combined anterior cruciate ligament and anterolateral ligament reconstruction technique with a minimum 2-year follow-up. *Am J Sports Med*. 2015;43(7):1598-1605.
45. Tashman S, Collon D, Anderson K, Kolowich P, Anderst W. Abnormal rotational knee motion during running after anterior cruciate ligament reconstruction. *Am J Sports Med*. 2004;32(4):975-983.
46. Tavlo M, Eljaja S, Jensen JT, Siersma VD, Krogsgaard MR. The role of the anterolateral ligament in ACL insufficient and reconstructed knees on rotatory instability: a biomechanical study on human cadavers. *Scand J Med Sci Sports*. 2016;26(8):960-966.
47. Terry GC, Norwood LA, Hughston JC, Caldwell KM. How iliotibial tract injuries of the knee combine with acute anterior cruciate ligament tears to influence abnormal anterior tibial displacement. *Am J Sports Med*. 1993;21(1):55-60.
48. Trojani C, Beauvilliers P, Burdin G, et al. Revision ACL reconstruction: influence of a lateral tenodesis. *Knee Surg Sports Traumatol Arthrosc*. 2012;20(8):1565-1570.
49. Trojani C, Sbihi A, Dijan P, et al. Causes for failure of ACL reconstruction and influence of meniscectomies after revision. *Knee Surg Sports Traumatol Arthrosc*. 2011;19(2):196-201.
50. Vadalà AP, Iorio R, De Carli A, et al. An extra-articular procedure improves the clinical outcome in anterior cruciate ligament reconstruction with hamstrings in female athletes. *Int Orthop*. 2013;37:187-192.
51. Yagi M, Wong EK, Kanamori A, et al. Biomechanical analysis of an anatomic anterior cruciate ligament reconstruction. *Am J Sports Med*. 2002;30(5):660-666.
52. Yasuda K, Tanabe Y, Kondo E, et al. Anatomic double-bundle anterior cruciate ligament reconstruction. *Arthroscopy*. 2010;26:S21-S34.